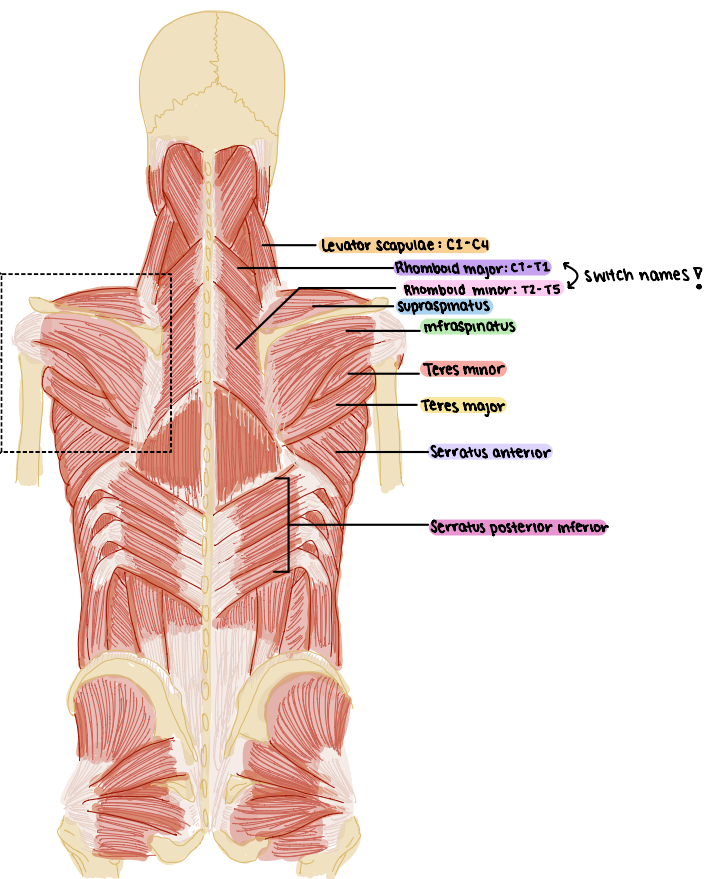
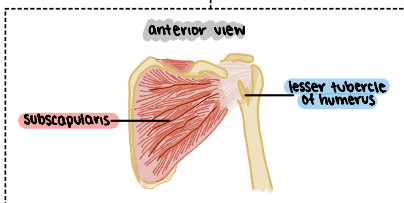
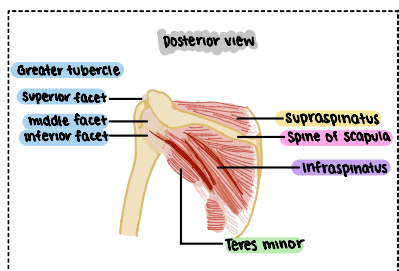
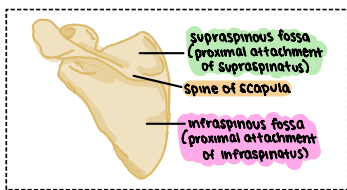
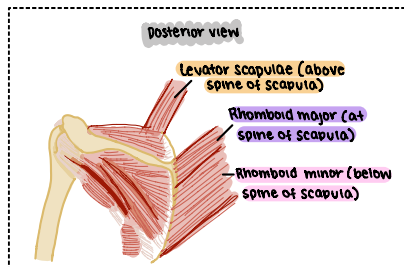
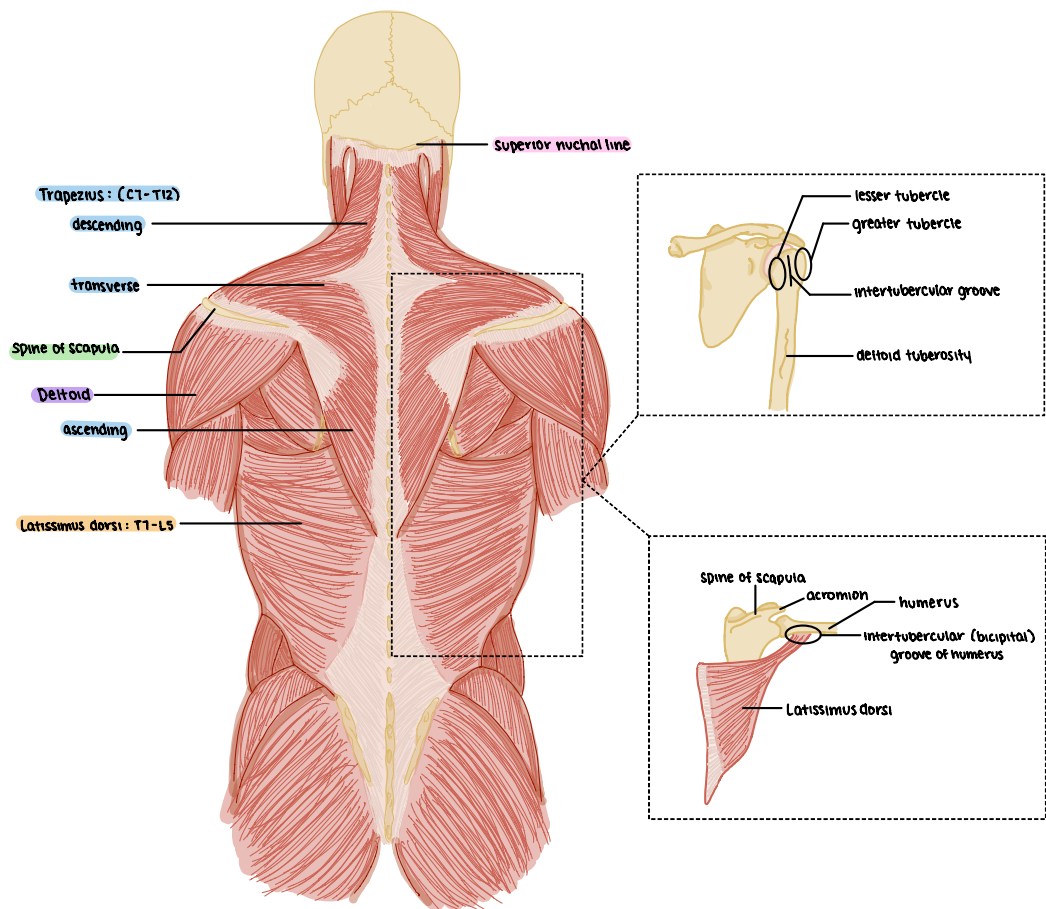
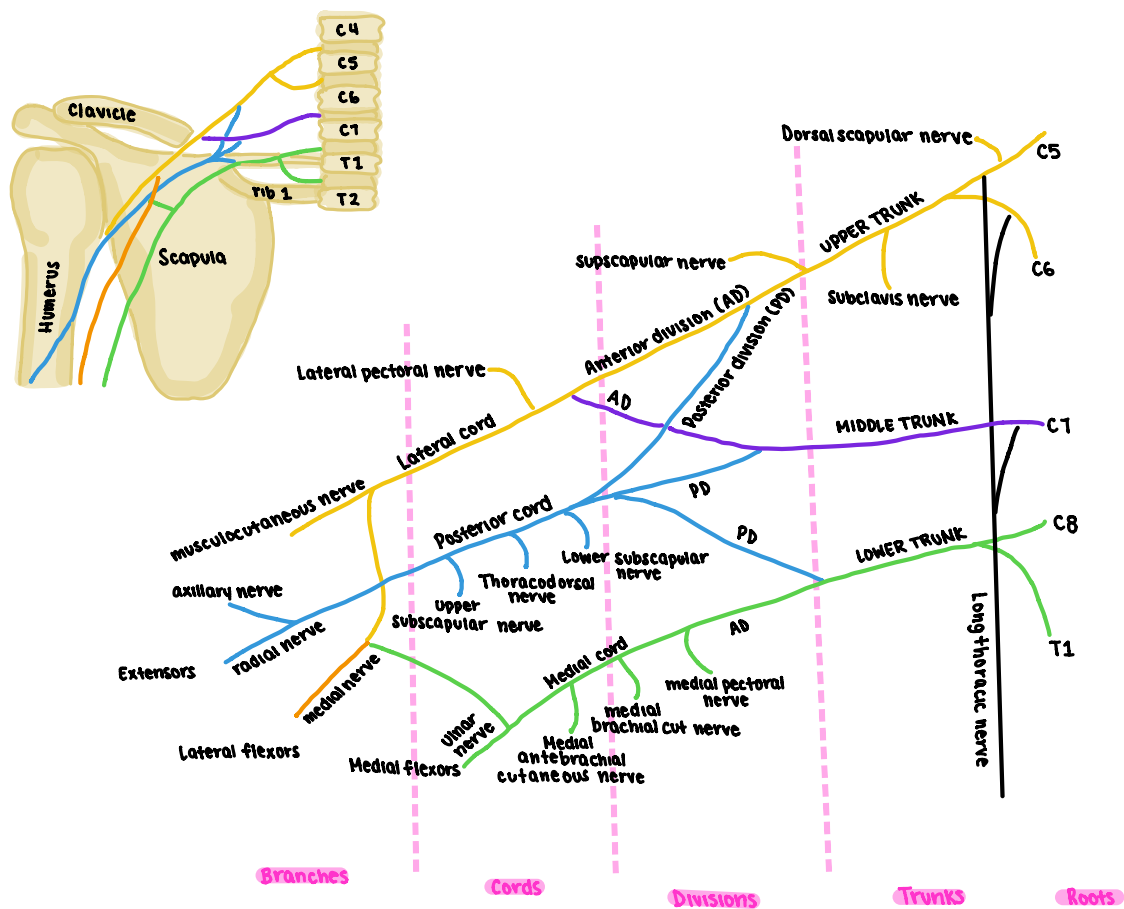


# ass 1



# QAS 2



#### Quiz 1:

1. Which of the following is innervated by the posterior ramus of spinal nerves?
2. What makes up the perimeter of the intervertebral foramen? pedicle
3. Think about what happens when you are writing, which is/are true? humerus flexed, forearm supinated
4. Where does the transversospinales attach to? transverse and spinous processes
5. Which structures carry motor and sensory information? spinal nerve and ramus
6. Which is the most superficial? longissimus > semispinalis = multifidus = rotatores > levator costarum (deepest)
7. Where does the pedicle meet lamina? transverse process
8. What plane does the abduction of the humerus occur at? coronal plane
9. Where does the longitudinal ligament located? present at anterior vertebral canal
10. Characteristic(s) of thoracic vertebra include(s): looks like a giraffe, heart shaped body

#### Assignment 28

- If C1 was cut, how does this affect abduction of humerus?
- If medial trunk was cut, how is abduction of humerus affected?